

NEET PG Anatomy Sample Paper-1

Duration: 15 Minutes

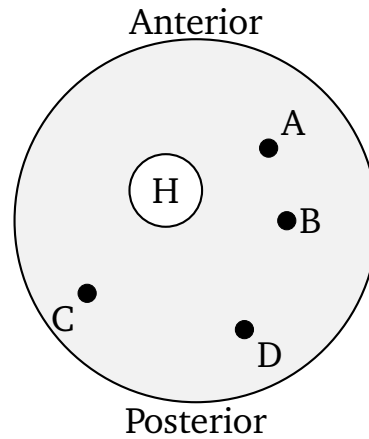
Maximum Marks: 68

Instructions

- This paper contains **17** Multiple Choice Questions.
- Each correct answer carries **+4** mark. Incorrect answer: **-1** marks. Only **one** correct option.
- Unattempted questions carry **0** marks.
- Use of mobile phones, smartwatches, or any electronic gadgets is strictly prohibited.

- Q1.** A 45-year-old male presents with a stab wound to the lower neck, just superior to the medial third of the clavicle. On examination, there is decreased breath sounds on the affected side and a chest X-ray reveals a pneumothorax. Injury to which of the following fascial layers and structures best explains this condition?
- (A) Investing layer of deep cervical fascia and the apex of the lung
(B) Pretracheal fascia and the subclavian artery
(C) Sibson's fascia and the cervical pleura (suprapleural membrane)
(D) Prevertebral fascia and the sympathetic trunk
- Q2.** A 28-year-old professional tennis player complains of numbness and tingling along the medial aspect of her forearm and hand, accompanied by weakness in flexing her wrist against resistance. A schematic cross-section of the upper arm is illustrated below to map the affected neurovascular pathway. Which labeled structure represents the primary nerve involved in this presentation?





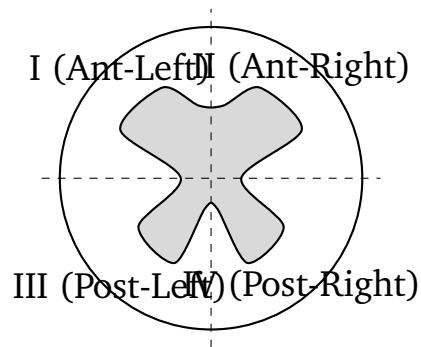
- (A) Structure A
- (B) Structure B
- (C) Structure C
- (D) Structure D

Q3. During a routine newborn assessment, a pediatrician notes a smooth, flat philtrum, a thin upper lip, and short palpebral fissures. The mother admits to chronic alcohol consumption during early pregnancy. Which embryological process was primarily disrupted by this teratogenic insult?

- (A) Failure of fusion between the maxillary prominence and lateral nasal prominence
- (B) Defective migration and proliferation of neural crest cells into the frontonasal prominence
- (C) Incomplete breakdown of the buccopharyngeal membrane
- (D) Failure of fusion between the two medial nasal prominences

Q4. A patient undergoing a neurological examination demonstrates a loss of pain and temperature sensation on the left side of the body starting below the neck, combined with a loss of conscious proprioception and discriminative touch on the right side of the body below the level of the lesion. A spinal cord schema is provided below. Which quadrant contains the localized lesion causing this presentation?





- (A) Quadrant I
- (B) Quadrant II
- (C) Quadrant III
- (D) Quadrant IV

Q5. An anatomical pathologist examines a biopsy sample taken from the gastrointestinal tract. The slide reveals an epithelial lining consisting of single-layered tall cells with basally placed oval nuclei, interspersed with mucin-secreting goblet cells, but completely lacking a brush border of microvilli or explicit muscularis mucosae specialized configurations. From which specific region was this tissue most likely harvested?

- (A) Terminal ileum
- (B) Stomach (Fundus)
- (C) Gallbladder mucosa
- (D) Transverse colon

Q6. A 62-year-old female undergoes an open cholecystectomy. While isolating the cystic artery within the cystohepatic triangle (Calot's triangle), the surgical resident accidentally causes significant arterial bleeding. To control the hemorrhage, the attending surgeon compresses the main artery running inside the anterior boundary of the epiploic foramen. Which of the following structures forms the immediate posterior boundary of this foramen?

- (A) Portal vein, hepatic artery proper, and bile duct
- (B) Inferior vena cava and right crus of the diaphragm

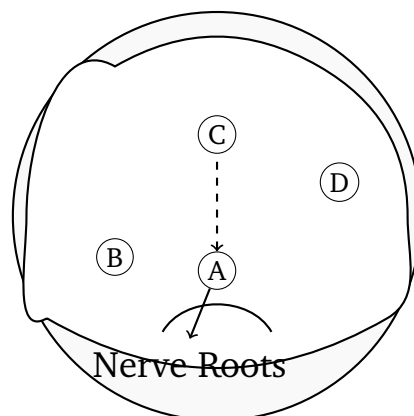


- (C) Caudate lobe of the liver
- (D) First part of the duodenum

Q7. A 34-year-old male presents with severe hoarseness and a weak, breathy voice following a thyroidectomy for a large multinodular goiter. Laryngoscopic evaluation reveals that the right vocal fold is fixed in an abducted position during phonation. The nerve responsible for innervating the affected muscle runs in close proximity to which vascular structure during its terminal cervical course?

- (A) Inferior thyroid artery
- (B) Superior thyroid artery
- (C) Occipital artery
- (D) Internal thoracic artery

Q8. A schematic diagram representing a transverse slice of the brain stem at the level of the superior colliculus is shown below. A patient presents with contralateral hemiparesis and ipsilateral paralysis of ocular adduction and vertical gaze, consistent with Weber's syndrome. Which letter corresponds to the tract or nerve root lesion responsible for the ipsilateral ocular manifestation?



- (A) Structure A
- (B) Structure B
- (C) Structure C



(D) Structure D

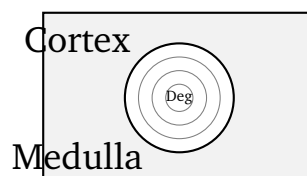
Q9. A child is diagnosed with a congenital cardiac defect characterized by an abnormal communication between the right and left atria. Embryological analysis reveals a complete failure in the resorption of the upper part of the septum primum. This defect will specifically manifest as which variant of atrial septal defect (ASD)?

- (A) Ostium primum defect
- (B) Ostium secundum defect
- (C) Sinus venosus defect
- (D) Coronary sinus defect

Q10. A 55-year-old chronic smoker presents with severe pain in his left buttock and thigh that worsens significantly during walking and is relieved by rest (intermittent claudication). Angiography reveals a significant atherosclerotic occlusion at the origin of the internal iliac artery. Which of the following collateral pathways is most critical in maintaining blood supply to the distribution of the obturator artery?

- (A) Anastomosis with the deep circumflex iliac artery
- (B) Anastomosis with the pubic branch of the inferior epigastric artery
- (C) Anastomosis with the superior gluteal artery
- (D) Anastomosis with the lateral circumflex femoral artery

Q11. An electron micrograph of a lymphoid organ section shows unique corpuscles composed of concentrically arranged, flattened epithelial reticular cells showing signs of keratinization and central degeneration. A structural bounding matrix layout is mapped below. Which organ's histomorphology is represented by this arrangement?



- (A) Palatine tonsil
- (B) Spleen
- (C) Thymus
- (D) Lymph node

Q12. A 19-year-old male is brought to the emergency department after a motorcycle crash. Physical examination reveals an inability to dorsiflex or evert his right foot, resulting in a classic foot drop gait. There is also a loss of sensation on the dorsum of the foot and the lateral aspect of the leg. The injured nerve wraps around which of the following skeletal landmarks?

- (A) Medial malleolus of the tibia
- (B) Neck of the fibula
- (C) Sustentaculum tali of the calcaneus
- (D) Lateral epicondyle of the femur

Q13. A 50-year-old executive complains of double vision when looking downward and inward while descending stairs. Examination reveals a subtle extorsion of the affected eye when looking straight ahead. The patient frequently tilts his head to the opposite side to minimize diplopia. Which cranial nerve nucleus is localized at the level of the injury?

- (A) Midbrain at the level of the superior colliculus
- (B) Midbrain at the level of the inferior colliculus
- (C) Pons at the level of the facial colliculus
- (D) Medulla at the level of the hypoglossal triangle

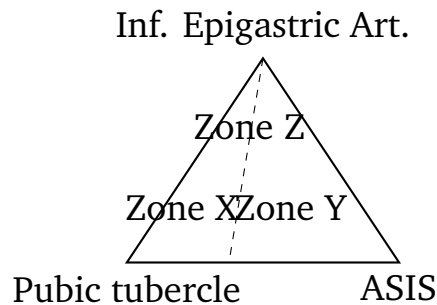
Q14. During a deep neck dissection, a surgeon isolates the structures passing through the gap between the superior and middle pharyngeal constrictor muscles. Damage to the neural structures in this specific boundary space would impair which physiological reflex or function?

- (A) Sensory arm of the gag reflex from the posterior third of the tongue



- (B) Motor innervation to the tensor veli palatini muscle
- (C) Taste sensation from the anterior two-thirds of the tongue
- (D) Parasympathetic secretion from the submandibular gland

Q15. A 42-year-old male is diagnosed with an inguinal hernia. During surgical repair, the resident identifies a sac that emerges medial to the inferior epigastric vessels through a weakness in the posterior wall of the inguinal canal. The geometric configuration of this abdominal area is diagrammed below. Which labeled zone represents the path taken by this direct inguinal hernia?



- (A) Zone X (Hesselbach's triangle)
 - (B) Zone Y (Deep inguinal ring)
 - (C) Zone Z (Femoral ring canal)
 - (D) None of the designated zones
- Q16.** A 68-year-old man presents with signs of urinary retention and a digital rectal exam reveals marked symmetric enlargement of the prostate gland. Biopsies confirm benign prostatic hyperplasia (BPH). Histological examination of this condition typically demonstrates hyperplasia originating predominantly within which anatomical subdivision of the prostate?
- (A) Peripheral zone
 - (B) Central zone
 - (C) Transition zone
 - (D) Anterior fibromuscular stroma



- Q17.** An MRI of a 60-year-old patient reveals an acoustic neuroma localised within the internal acoustic meatus, completely compressing the contents of the canal. In addition to hearing loss and vestibular symptoms, which clinical sign will most likely be observed due to local compression of neighbouring structures?
- (A) Loss of general sensation from the anterior two-thirds of the tongue
 - (B) Hyperacusis and loss of taste from the anterior two-thirds of the tongue
 - (C) Deviation of the uvula toward the side of the lesion
 - (D) Ptosis and miosis due to sympathetic pathway block



Detailed Solutions

Q1.

Solution**Concept:**

The root of the neck contains critical neurovascular structures and extensions of the thoracic cavity covered by specialized fascial linings. Sibson's fascia (the suprapleural membrane) is a dense connective tissue layer that extends from the transverse process of the C7 vertebra to the inner border of the first rib.

Solution:

- (a) A stab wound located immediately superior to the medial third of the clavicle breaches the root of the neck, directly menacing the cervical pleura and the underlying cupula or apex of the lung.
- (b) The cervical pleura projects roughly 2.5 to 5 cm above the first costal cartilage and 2.5 cm superior to the medial third of the clavicle, making it highly vulnerable to penetrating trauma in this specific zone.
- (c) Sibson's fascia provides architectural protection to this dome-like thoracic projection. When breached, atmospheric air enters the pleural cavity, abolishing the negative intrapleural pressure.
- (d) Other structures listed, like the pretracheal fascia or the prevertebral layers, cover visceral and muscular spaces that do not directly line the pleural cupula.

Final Answer: Sibson's fascia and the cervical pleura (suprapleural membrane)

Answer: (C)

[Go Back to Question 1](#)



Q2.

Solution**Concept:**

A cross-section of the mid-upper arm maps distinct neurovascular compartments. Sensory innervation of the medial forearm/hand and motor innervation for wrist flexion are primarily provided by the ulnar nerve ($C_8 - T_1$), which travels through the anterior compartment before piercing the medial intermuscular septum.

Solution:

- (a) The patient demonstrates classic features of ulnar nerve compression, showcasing sensory deficits along the medial aspect of the hand and weakness in the flexor carpi ulnaris muscle.
- (b) In a schematic cross-section of the mid-arm, the humerus (H) occupies the central-medial space, dividing muscles into anterior and posterior functional groups.
- (c) Structure A represents the median nerve, which tracks closely with the brachial artery in the anterior-medial neurovascular bundle.
- (d) Structure B corresponds to the ulnar nerve as it runs along the medial intermuscular septum before passing behind the medial epicondyle into the posterior space.
- (e) Structure C represents the radial nerve traveling in the spiral groove within the posterior compartment, while D represents the profunda brachii artery.

Final Answer: Structure B

Answer: (B)

[Go Back to Question 2](#)



Q3.

Solution**Concept:**

Fetal alcohol syndrome (FAS) results from maternal alcohol ingestion during critical windows of organogenesis. This teratogen specifically impairs neural crest cell survival, proliferation, and migration into the frontonasal prominence, leading to classic midface defects.

Solution:

- (a) The clinical presentation of a smooth philtrum, thin vermilion border of the upper lip, and short palpebral fissures represents the diagnostic facial phenotype of Fetal Alcohol Syndrome.
- (b) The frontonasal prominence gives rise to the forehead, bridge of the nose, and the medial and lateral nasal prominences during early craniofacial development.
- (c) Alcohol exerts a direct toxic effect on neural crest cells, inducing premature apoptosis and downregulating critical signaling pathways needed for migration.
- (d) Deficient cellular migration into the frontonasal prominence causes structural hypoplasia of the medial nasal processes, which normally form the philtrum.
- (e) Failures in maxillary and lateral nasal prominence fusion lead instead to cleft lip or cleft palate defects, rather than the specific smooth philtrum observed here.

Final Answer: Defective migration and proliferation of neural crest cells into the frontonasal prominence

Answer: (B)

[Go Back to Question 3](#)



Q4.

Solution**Concept:**

The Brown-Séquard syndrome results from a hemisection of the spinal cord. It presents with ipsilateral loss of proprioception, vibration, and fine touch below the lesion due to dorsal column damage, combined with contralateral loss of pain and temperature sensation due to spinothalamic tract disruption.

Solution:

- (a) The patient presents with loss of pain and temperature on the left side, which implies damage to the right-sided crossed lateral spinothalamic tract.
- (b) Concurrently, the loss of conscious proprioception and discriminative touch on the right side isolates the injury to the right dorsal columns (fasciculus gracilis and cuneatus).
- (c) Since both pathways indicate a lesion localized to the right side of the spinal cord, we must evaluate the anterior and posterior quadrants of that side.
- (d) The lesion encompasses both the anterior and posterior components of the right hemi-cord. However, the definitive localized injury causing the profound dorsal column deficit resides predominantly in the posterior quadrant.
- (e) Looking at the cross-sectional schema, Quadrant IV accurately represents the right posterior quadrant of the spinal cord matrix containing these dense sensory pathways.

Final Answer: Quadrant IV

Answer: (D)

[Go Back to Question 4](#)



Q5.

Solution**Concept:**

The histological architecture of the gastrointestinal tract varies according to functional specialization. The gallbladder mucosa features tall simple columnar epithelial cells specialized for water absorption, interspersed with occasional mucin glands, but it possesses neither a muscularis mucosae nor a true submucosa.

Solution:

- (a) The description highlights simple columnar epithelial cells with basal nuclei and goblet cells, but emphasizes the absolute absence of a muscularis mucosae.
- (b) The stomach mucosa features simple columnar epithelium but lacks goblet cells entirely, as its surface is composed of mucous neck cells and gastric pits.
- (c) The ileum and transverse colon both contain prominent goblet cells and a distinct microvillar brush border, but they strictly possess a well-defined muscularis mucosae layer.
- (d) The gallbladder mucosa is thrown into deep temporary folds resembling villi, but it can be differentiated by the total absence of a muscularis mucosae and submucosa.
- (e) Epithelial cells here absorb water and electrolytes to concentrate bile, and mucosal glands near its neck secrete protective mucin, matching the histological profile.

Final Answer: Gallbladder mucosa

Answer: (C)

[Go Back to Question 5](#)



Q6.

Solution**Concept:**

The epiploic foramen (foramen of Winslow) is the anatomical communication between the greater and lesser peritoneal sacs. It is bounded by key vascular and visceral structures that must be well-understood during Pringle's maneuver to control hepatic bleeding.

Solution:

- (a) When severe bleeding occurs from the cystic artery during a cholecystectomy, surgeons perform temporary occlusion of the hepatic pedicle within the hepatoduodenal ligament.
- (b) The hepatoduodenal ligament forms the immediate anterior boundary of the epiploic foramen, enclosing the portal vein, proper hepatic artery, and common bile duct.
- (c) To compress these vessels, the surgeon passes a finger into the foramen, pressing anteriorly against the structures while feeling the posterior boundary.
- (d) The posterior boundary of this narrow anatomical opening is formed directly by the peritoneal covering of the retroperitoneal inferior vena cava and the right crus of the diaphragm.
- (e) The superior boundary is formed by the caudate lobe of the liver, while the inferior boundary is formed by the first part of the duodenum.

Final Answer: Inferior vena cava and right crus of the diaphragm

Answer: (B)

[Go Back to Question 6](#)



Q7.

Solution**Concept:**

The recurrent laryngeal nerve innervates all intrinsic muscles of the larynx except the cricothyroid muscle. During its course in the neck, it shares an intimate, high-risk anatomical relationship with the terminal branches of the inferior thyroid artery.

Solution:

- (a) Injury to the recurrent laryngeal nerve during thyroid surgery results in vocal fold paralysis, causing symptoms like hoarseness and a breathy voice due to improper vocal cord adduction.
- (b) The right recurrent laryngeal nerve loops around the right subclavian artery and ascends in the tracheoesophageal groove toward the lower border of the cricoid cartilage.
- (c) Near the lower pole of the thyroid gland, the nerve crosses or intertwines directly with the terminal branches of the inferior thyroid artery.
- (d) This close proximity makes the nerve highly susceptible to traction, clamping, or transection injuries during ligation of the artery during a thyroidectomy.
- (e) Conversely, the superior thyroid artery tracks closely with the external branch of the superior laryngeal nerve near the upper pole of the gland.

Final Answer: Inferior thyroid artery

Answer: (A)

[Go Back to Question 7](#)



Q8.

Solution**Concept:**

Weber's syndrome is a vascular ventromedial midbrain syndrome typically caused by occlusion of the paramedian branches of the posterior cerebral artery. It damages the descending corticospinal tract and the exiting oculomotor nerve rootlets simultaneously.

Solution:

- (a) The clinical presentation includes contralateral hemiparesis due to damage of the uncrossed corticospinal fibers traveling through the crus cerebri of the midbrain.
- (b) The ipsilateral manifestation involves oculomotor nerve (*CN III*) paralysis, presenting as a down-and-out eye, ptosis, and a dilated, non-reactive pupil.
- (c) At the level of the superior colliculus, the oculomotor nerve rootlets originate from the oculomotor nucleus and travel anteriorly through the red nucleus.
- (d) These rootlets emerge into the interpeduncular fossa by passing through the medial aspect of the crus cerebri, making them vulnerable to ventromedial lesions.
- (e) In the provided midbrain TikZ schema, label A marks the exiting oculomotor nerve fibers within the interpeduncular fossa, which accounts for the ipsilateral ocular presentation.

Final Answer: Structure A

Answer: (A)

[Go Back to Question 8](#)



Q9.

Solution**Concept:**

The development of the interatrial septum involves the coordinated growth and remodeling of two septal walls: the septum primum and the septum secundum. Programmed cell death creates openings within these walls to maintain physiological right-to-left shunting during fetal life.

Solution:

- (a) The septum primum grows downward toward the endocardial cushions, leaving a temporary opening called the ostium primum, which is later completely obliterated.
- (b) Before the ostium primum closes, scheduled apoptosis in the upper portion of the septum primum creates a new opening known as the ostium secundum.
- (c) If resorption of the upper part of the septum primum fails to occur properly or is excessive, the opening cannot be properly covered by the developing septum secundum.
- (d) This embryological failure leads to an ostium secundum atrial septal defect, which is the most common clinical variant of interatrial communication.
- (e) An ostium primum defect occurs due to failure of the septum primum to fuse with the endocardial cushions, which is distinctly separate from upper resorption defects.

Final Answer: Ostium secundum defect

Answer: (B)

[Go Back to Question 9](#)



Q10.

Solution**Concept:**

The pelvis and upper thigh are rich in vascular anastomoses that preserve blood flow when major pelvic arteries become occluded. The obturator artery, a branch of the anterior division of the internal iliac artery, can receive collateral flow via the inferior epigastric system.

Solution:

- (a) When the origin of the internal iliac artery is occluded, its downstream branches, including the obturator artery, experience an immediate drop in perfusion pressure.
- (b) The obturator artery normally gives off a small pubic branch that ascends along the posterior aspect of the pubis to anastomose behind the pubic symphysis.
- (c) This pubic branch communicates directly with the pubic branch arising from the inferior epigastric artery, which is a branch of the patent external iliac artery.
- (d) In cases of internal iliac obstruction, blood flows retrogradely from the external iliac through this pubic anastomosis to preserve perfusion to the medial thigh.
- (e) This collateral pathway is anatomically variable and is closely related to the corona mortis, an important surgical landmark during pelvic and hernia repairs.

Final Answer: Anastomosis with the pubic branch of the inferior epigastric artery

Answer: (B)

[Go Back to Question 10](#)



Q11.

Solution**Concept:**

The architectural hallmark of the thymus is the presence of Hassall's corpuscles located strictly within its medullary regions. These unique structures are formed by concentrically arranged, eosinophilic epithelial reticular cells.

Solution:

- (a) The description provided features a classic lymphoid architectural outline containing specialized multicellular structures exhibiting micro-keratinization and central degeneration within a mapped cortex-medulla framework.
- (b) Hassall's corpuscles (thymic corpuscles) vary drastically in size and are uniquely pathognomonic for the mammalian thymus medulla, distinguishing it instantly from all other peripheral lymphoid tissues.
- (c) Epithelial reticular cells secrete various cytokines like thymic stromal lymphopoietin.
- (d) Looking at the other peripheral options, the palatine tonsils are readily distinguished by stratified squamous non-keratinized epithelial linings and crypt structures running deeply into the underlying tissue.
- (e) The spleen lacks any cortex-medulla layout and contains distinct red and white pulp zones, whereas typical lymph nodes feature prominent lymphatic nodules with germinal centers and subcapsular sinus spaces.

Final Answer: Thymus

Answer: (C)

[Go Back to Question 11](#)



Q12.

Solution**Concept:**

The common peroneal (fibular) nerve originates from the sciatic nerve and tracks laterally along the popliteal fossa. It spirals subcutaneously around the bony neck of the fibula, where it is highly susceptible to external blunt force trauma, compression, or fractures.

Solution:

- (a) The presentation highlights an inability to execute foot dorsiflexion and eversion, creating a classic high-steppage foot drop gait alongside anesthesia over the anterior-lateral lower leg and pedal dorsum.
- (b) The common peroneal nerve bifurcates precisely at the lateral aspect of the fibular neck into the superficial peroneal nerve and the deep peroneal nerve branches.
- (c) The superficial branch supplies the lateral compartment muscles responsible for eversion (peroneus longus and brevis) and carries cutaneous sensation from most of the dorsal skin.
- (d) The deep branch drives the anterior compartment muscles tasked with dorsiflexion (tibialis anterior, extensor digitorum longus) and supplies the skin of the first web space.
- (e) Injury to the nerve at its subcutaneous vulnerable pivot around the fibular neck knocks out both branches simultaneously, making this structural point the primary root site of failure.

Final Answer: Neck of the fibula

Answer: (B)

[Go Back to Question 12](#)



Q13.

Solution**Concept:**

The trochlear nerve (CN IV) emerges from the dorsal aspect of the lower midbrain at the level of the inferior colliculus. It uniquely decussates within the superior medullary velum before coursing anteriorly to innervate the contralateral superior oblique extraocular muscle.

Solution:

- (a) The patient demonstrates classic clinical signs of trochlear nerve palsy, reporting vertical diplopia that worsens significantly when tracking an object downward and inward while descending stairs.
- (b) The superior oblique muscle normally functions to depress, intort, and abduct the globe. When paralyzed, the unopposed action of the inferior oblique muscle produces relative extorsion.
- (c) To compensate for this mechanical extorsion and realign visual inputs, patients characteristically tilt their heads toward the contralateral healthy shoulder to abolish the distressing double vision.
- (d) The somatic motor nucleus of the trochlear nerve is localized within the ventromedial grey matter of the midbrain, situated just inferior to the larger oculomotor complex.
- (e) This matches the exact anatomical horizon of the inferior colliculus, making injuries at this specific brainstem section responsible for the localized cranial nerve deficit.

Final Answer: Midbrain at the level of the inferior colliculus

Answer: (B)

[Go Back to Question 13](#)



Q14.

Solution**Concept:**

The pharyngeal wall features structural intervals or gaps between its muscular constrictor layers that permit the passage of specialized neurovascular elements. The space between the superior and middle constrictors transmits the glossopharyngeal nerve (CN IX) and style-associated structures.

Solution:

- (a) Deep dissection of the lateral pharyngeal wall exposes a key triangular gap bounded superiorly by the superior constrictor and inferiorly by the middle constrictor muscle fibers.
- (b) Traveling through this muscular interval are the stylopharyngeus muscle, the stylohyoid ligament, and the essential sensory fibers of the glossopharyngeal nerve (CN IX) heading toward the base.
- (c) The glossopharyngeal nerve supplies general somatic sensation and special visceral afferent taste streams to the posterior third of the tongue, tonsils, and upper oropharynx.
- (d) It forms the afferent (sensory) limb of the pharyngeal or gag reflex. Tactile stimulation of the posterior tongue sends signals via this nerve to the nucleus solitarius.
- (e) Consequently, damage to the neural elements traversing this specific anatomical gap directly blunts or abolishes the sensory trigger needed to initiate the protective gag response.

Final Answer: Sensory arm of the gag reflex from the posterior third of the tongue

Answer: (A)

[Go Back to Question 14](#)



Q15.

Solution**Concept:**

The inguinal wall is demarcated by Hesselbach's triangle, an area of anatomical weakness in the lower anterior abdominal wall. It is bounded medially by the rectus abdominis muscle, laterally by the inferior epigastric vessels, and inferiorly by the inguinal ligament.

Solution:

- (a) The case describes an inguinal hernia sac that passes medial to the inferior epigastric vessels, skipping the deep inguinal ring to protrude directly through the fascia transversalis.
- (b) This clinical mechanism represents a direct inguinal hernia, which is caused by an acquired weakness in the structural integrity of the posterior inguinal wall.
- (c) Looking at the provided geometric diagram, the zone located medial to the inferior epigastric artery line and above the inguinal ligament base represents this precise space.
- (d) Zone X corresponds precisely to Hesselbach's triangle (the medial inguinal fossa), making it the definitive corridor utilized by direct hernias during structural failure.
- (e) Zone Y maps the area lateral to the epigastric vessels where indirect hernias enter via the deep ring, while Zone Z represents the deeper retroperitoneal abdominal space.

Final Answer: Zone X (Hesselbach's triangle)

Answer: (A)

[Go Back to Question 15](#)



Q16.

Solution**Concept:**

The human prostate gland is divided into distinct zones according to McNeal's concept of glandular anatomy. These zones exhibit unique histomorphologies and vary greatly in their susceptibility to hyperplastic and neoplastic transformations.

Solution:

- (a) The patient presents with clinical signs of lower urinary tract obstruction caused by mechanical narrowing of the prostatic urethra due to Benign Prostatic Hyperplasia.
- (b) Histologically, BPH is characterized by nodular proliferation of both stromal and epithelial elements. This process takes place almost exclusively within the transition zone.
- (c) The transition zone surrounds the proximal segment of the prostatic urethra. As these nodular masses expand, they immediately compress the urethral lumen, driving clinical urinary retention.
- (d) Conversely, prostate adenocarcinoma originates predominantly within the peripheral zone, which forms the posterior and lateral aspect of the gland and is palpable rectally.
- (e) The central zone surrounds the ejaculatory ducts and is rarely involved in these common hyperplastic processes, making the transition zone the definitive site of origin.

Final Answer: Transition zone

Answer: (C)

[Go Back to Question 16](#)



Q17.

Solution**Concept:**

The internal acoustic meatus acts as a narrow bony conduit through the petrous part of the temporal bone, transmitting the vestibulocochlear nerve (*CN VIII*), the facial nerve (*CN VII*), and the labyrinthine artery.

Solution:

- (a) An acoustic neuroma (vestibular schwannoma) originating within the internal acoustic meatus expands progressively, filling the rigid bony canal and compressing all structures running beside it.
- (b) Compression of the vestibulocochlear nerve accounts for the patient's initial symptoms, which typically manifest as sensorineural hearing loss, tinnitus, and vestibular disequilibrium.
- (c) The facial nerve (*CN VII*) shares this cramped osseous canal. Progressive local tumor expansion leads to compression of its motor, parasympathetic, and sensory components.
- (d) Damage to the facial nerve fibers results in ipsilateral lower motor neuron facial weakness, loss of lacrimation, loss of the stapedial reflex causing hyperacusis, and loss of taste.
- (e) The taste deficit specifically involves the anterior two-thirds of the tongue via the chorda tympani branch, matching the clinical signs linked with local meatal compression.

Final Answer: Hyperacusis and loss of taste from the anterior two-thirds of the tongue

Answer: (B)

[Go Back to Question 17](#)



Answer Key

Q	Ans	Q	Ans	Q	Ans	Q	Ans	Q	Ans
1	C	2	B	3	B	4	D	5	C
6	B	7	A	8	A	9	B	10	B
11	C	12	B	13	B	14	A	15	A
16	C	17	B						

