

# NEET-PG Forensic Medicine Sample Paper-4

Duration: 10 Minutes

Maximum Marks: 40

## Instructions

- This paper contains **10** Multiple Choice Questions.
- Each correct answer carries **+4** mark. Incorrect answer: **-1** marks. Only **one** correct option.
- Unattempted questions carry **0** marks.
- Use of mobile phones, smartwatches, or any electronic gadgets is strictly prohibited.

**Q1.** A 32-year-old construction worker is brought to the emergency department after a fall from a height of approximately 20 feet. On examination, there is a laceration over the right temporal region. Radiological evaluation reveals a linear fracture of the right temporal bone. During autopsy two days later following his demise, the forensic pathologist notes a collection of blood between the inner surface of the skull and the dura mater, which does not cross the cranial sutures. Which of the following vessels is most likely lacerated in this condition?

- (A) Middle meningeal artery
- (B) Superior sagittal sinus
- (C) Bridging cortical veins
- (D) Anterior cerebral artery

**Q2.** A 28-year-old married woman is brought to the tertiary care hospital with severe abdominal pain, vomiting, and a smelling breath resembling bitter almonds. Despite active resuscitation, she succumbs to her illness. The police suspect foul play by her in-laws. During the medico-legal autopsy, which of the following preservative solutions must be strictly avoided for preserving viscera for chemical analysis?

- (A) Saturated solution of common salt



- (B) Rectified spirit
- (C) 10% Formalin
- (D) Potassium oxalate

**Q3.** A 45-year-old chronic alcoholic is brought to the casualty in an altered mental state with severe metabolic acidosis and a high anion gap. His friends state that he consumed cheap illicit liquor the previous evening. Fundoscopy reveals bilateral optic disc edema. Which of the following metabolic intermediates is primarily responsible for the ocular toxicity observed in this patient?

- (A) Acetaldehyde
- (B) Formic acid
- (C) Formaldehyde
- (D) Glycolic acid

**Q4.** A judicial magistrate requests a forensic expert to examine a medical practitioner accused of performing an illegal termination of pregnancy without the consent of the woman. Under which section of the Indian Penal Code (IPC) is the act of causing miscarriage without the woman's consent penalized?

- (A) Section 312 IPC
- (B) Section 313 IPC
- (C) Section 314 IPC
- (D) Section 315 IPC

**Q5.** During an institutional dispute involving a clinical trial negligence case, a medical specialist is summoned by the Court of Sessions to give expert testimony. The physician deliberately provides false evidence under oath to protect the institution. Under which section of the Indian Penal Code (IPC) can this medical practitioner be prosecuted for giving false evidence?

- (A) Section 191 IPC
- (B) Section 192 IPC

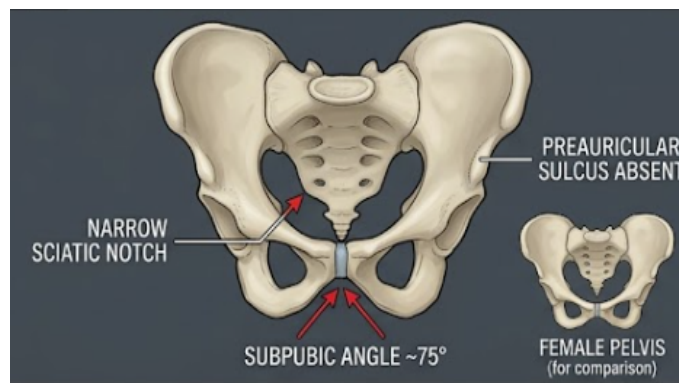


(C) Section 193 IPC

(D) Section 201 IPC

**Q6.** A body of an unknown adult male is retrieved from a river. The body is in an advanced stage of decomposition. To establish the biological profile of the deceased, the forensic anthropologist analyzes the pelvic morphology represented schematically below:

The specialist notes that the subpubic angle ( $\theta$ ) is approximately  $75^\circ$ , the sciatic notch is narrow, and the preauricular sulcus is absent. What is the most definitive conclusion regarding the sex of the individual?



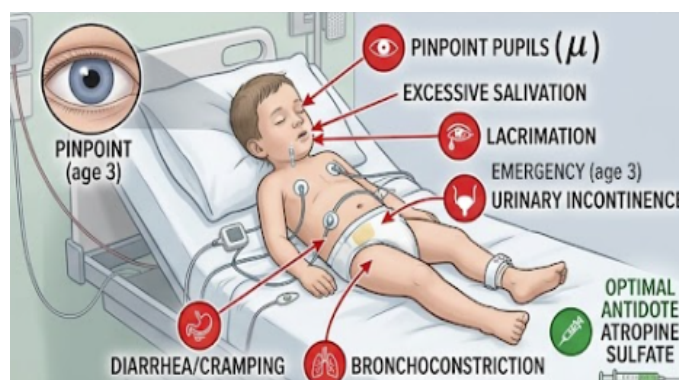
(A) Definitely Female

(B) Definitely Male

(C) Intersex individual

(D) Indeterminate due to advanced decomposition

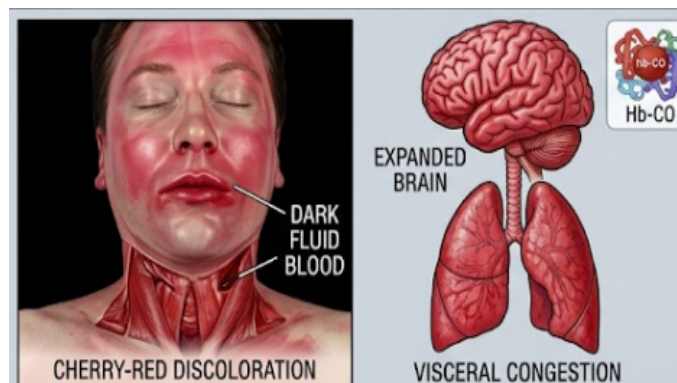
**Q7.** A 3-year-old child is accidentally brought to the emergency department after ingesting a clear liquid from a bottle kept in the garage. The clinical toxidrome progress is tracked on the timeline schematic below:



Which of the following pharmacological agents is the most appropriate initial antidote to reverse these specific life-threatening manifestations?

- (A) Pralidoxime
- (B) Atropine sulfate
- (C) Physostigmine
- (D) N-acetylcysteine

**Q8.** A young male is brought dead to the mortuary with history of a sudden collapse at a party. Autopsy reveals intense congestion of all internal organs, dark fluid blood, and a distinct cherry-red discoloration of the skin, muscles, and mucous membranes. The spectrophotometric shift of the hemoglobin complex ( $\alpha$  vs  $\beta$  bands) is schematically isolated below:



Which of the following toxic agents is most likely responsible for this post-mortem appearance?

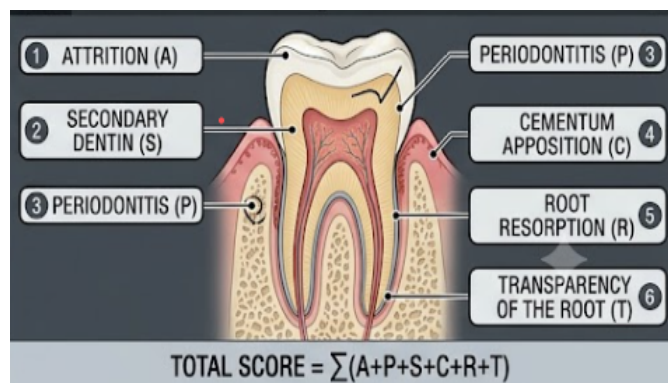
- (A) Carbon monoxide
- (B) Hydrogen sulfide
- (C) Phosphorus
- (D) Nitric acid

**Q9.** A medical practitioner is treating a patient with a history of chronic psychiatric illness. The patient shares specific intent to commit a violent assault against a named colleague. The physician fails to inform the police or the targeted individual, and the patient subsequently executes the assault. The physician is legally questioned regarding this failure. Which of the following terms correctly

defines the legal obligation of a doctor to protect third parties from a patient's predictable violence?

- (A) Res Ipsa Loquitur
- (B) Tarasoff Doctrine
- (C) Vicarious Liability
- (D) Volenti Non Fit Injuria

**Q10.** A skeletonized human remains sample is brought to the forensic science laboratory for age estimation. The forensic odontologist decides to apply Gustafson's method, evaluating structural parameters cross-sectionally as illustrated below:



Which of the following dental parameters is NOT a component used in Gustafson's criteria for age estimation?

- (A) Attrition
- (B) Paradoxical dentinogenesis
- (C) Root resorption
- (D) Cementum apposition

**Detailed Solutions****Q1.****Solution**

**Concept:** The question relates to the traumatic intracranial hemorrhages secondary to head injury. Cranial sutures limit the expansion of an epidural hematoma because the dura mater is tightly adherent to the skull at these suture lines.

**Solution:** Step 1: Analyze the clinical and radiological findings presented in the case. The patient has a linear fracture of the temporal bone following a significant fall, followed by a post-mortem finding of a localized blood collection between the skull and the dura mater that does not cross the suture lines.

Step 2: Identify the pathological entity based on these features. A collection of blood between the inner skull table and the dura mater defines an epidural (or extradural) hematoma. The restriction by cranial sutures confirms its extradural location, as the periosteal dura is firmly fixed at the sutural ligaments.

Step 3: Correlate the anatomical location with the most vulnerable vascular structure. The temporal bone is relatively thin, and running in a groove on its inner surface is the middle meningeal artery, a branch of the maxillary artery.

Step 4: Formulate the mechanism of injury. Traumatic fracture of the temporal bone lacerates the middle meningeal artery, leading to high-pressure arterial bleeding that strips the dura away from the skull bone, creating a biconvex or lens-shaped hematoma.

Step 5: Compare with other options. Bridging cortical veins are responsible for subdural hematomas, which cross suture lines. The superior sagittal sinus can cause epidural or subdural bleeds but is associated with sagittal fractures, not temporal fractures.

**Final Answer:**

**Answer:** (A)

[Go Back to Question 1](#)



Q2.

**Solution**

**Concept:** Chemical analysis of viscera requires preservation in specific solutions that do not react with or degrade the poison or substance suspected. When cyanide poisoning is suspected, the choice of preservative is critical to prevent chemical interference.

**Solution:** Step 1: Interpret the clinical presentation from the autopsy history. The characteristic presentation of a young married woman with severe abdominal distress and a distinct breath odor resembling bitter almonds points strongly toward acute cyanide poisoning.

Step 2: Evaluate the standard protocols for viscera preservation during a medico-legal autopsy. Saturated solution of common salt is the standard chemical preservative used for most routine poison cases in India, except in specific toxicological scenarios.

Step 3: Examine the compatibility of aldehydes with cyanide. Formalin (10% formaldehyde solution) must be completely avoided because formaldehyde chemically reacts with cyanide ions.

Step 4: Understand the specific chemical interaction. Formaldehyde combines with cyanide to form cyanohydrin complexes. This chemical reaction effectively binds the free cyanide ions present in the tissue samples.

Step 5: Determine the analytical consequence. Because the cyanide is converted into cyanohydrin, subsequent toxicological analysis via standard laboratory techniques will fail to detect the free poison, yielding a false-negative result that ruins the legal validity of the case.

**Final Answer:**

**Answer:** (C)

[Go Back to Question 2](#)



Q3.

**Solution**

**Concept:** The toxicity of toxic alcohols relies on their metabolic conversion within the human body via hepatic enzymes. The clinical presentation of severe high anion gap metabolic acidosis along with specific ocular toxicity indicates toxic alcohol poisoning.

**Solution:** Step 1: Identify the toxic agent from the clinical history. The consumption of cheap illicit liquor combined with severe metabolic acidosis, an elevated anion gap, and bilateral optic disc edema (retinal toxicity) is a classic manifestation of methanol poisoning.

Step 2: Trace the metabolic pathway of methanol in the liver. Methanol is initially metabolized by the enzyme alcohol dehydrogenase to form formaldehyde.

Step 3: Trace the subsequent metabolic step. Formaldehyde is rapidly converted by the enzyme aldehyde dehydrogenase into formic acid (or formate), which accumulates significantly in the body.

Step 4: Differentiate the roles of the intermediates in pathogenesis. While formaldehyde is highly reactive, its half-life is extremely short. It is the accumulation of formic acid that induces global cellular hypoxia by inhibiting cytochrome c oxidase in the mitochondrial respiratory chain.

Step 5: Relate the toxicity to the specific organ involvement. The optic nerve and the retina are highly sensitive to this disruption of oxidative phosphorylation. The accumulation of formic acid specifically causes retinal injury, optic disc edema, and permanent blindness.

**Final Answer:**

**Answer: (B)**

[Go Back to Question 3](#)



Q4.

**Solution**

**Concept:** Medical jurisprudence in India covers provisions within the Indian Penal Code (IPC) that deal with offenses relating to miscarriages, injuries to unborn children, and illegal termination of pregnancy without complying with established legal guidelines.

**Solution:** Step 1: Analyze the specific criminal act described in the legal request. The core offense committed by the medical practitioner is performing an illegal termination of pregnancy (causing miscarriage) deliberately without obtaining the explicit consent of the pregnant woman.

Step 2: Review Section 312 of the IPC. This section deals with causing miscarriage voluntarily with the consent of the woman, provided it is not done in good faith to save the woman's life. It carries a lesser penalty.

Step 3: Review Section 313 of the IPC. This specific section explicitly dictates the punishment for causing a miscarriage without the woman's consent. It is a much more severe, non-bailable offense that can carry life imprisonment.

Step 4: Review Sections 314 and 315 of the IPC. Section 314 deals with death caused by an act done with intent to cause miscarriage, while Section 315 covers acts done with intent to prevent a child being born alive or to cause it to die after birth.

Step 5: Match the scenario to the precise legal definition. Since the medical practitioner performed the abortion without the woman's consent, Section 313 IPC is the exact statutory provision violated.

**Final Answer:**

**Answer: (B)**

[Go Back to Question 4](#)



Q5.

**Solution**

**Concept:** Perjury and the fabrication of false evidence by any witness, including medical professionals acting as expert witnesses under oath in a court of law, are strictly punishable offenses governed by the Indian Penal Code to protect judicial integrity.

**Solution:** Step 1: Evaluate the actions of the medical specialist in the scenario. The physician was formally summoned as an expert witness by a Court of Sessions, took a legal oath, and then intentionally provided false testimony to shield their institution.

Step 2: Understand the distinction between giving and fabricating false evidence in the statutory definitions. Section 191 IPC defines the act of giving false evidence under a legal obligation or oath to state the truth.

Step 3: Understand Section 192 IPC, which outlines the parameters for fabricating false evidence, such as creating false circumstances or making false entries in medical records to influence judicial proceedings.

Step 4: Examine Section 193 IPC. This section provides the actual punishment for giving or fabricating false evidence in any stage of a judicial proceeding. The maximum punishment can extend up to seven years of imprisonment.

Step 5: Differentiate the applicable code for the prosecution. While Section 191 defines the crime, the formal prosecution and sentencing for giving false evidence under oath in a court of law are executed under Section 193 IPC.

**Final Answer:**

**Answer:** (C)

[Go Back to Question 5](#)



Q6.

**Solution**

**Concept:** Forensic anthropology relies heavily on skeletal morphology to establish sexual dimorphism. The pelvis is the most reliable skeletal element for sex determination in adults due to anatomical modifications adapted for childbirth in females.

**Solution:** Step 1: Analyze the provided morphological findings of the pelvic skeleton. The recovered bones show an explicit subpubic angle ( $\theta$ ) measured at approximately  $75^\circ$ , a narrow sciatic notch, and an absent preauricular sulcus.

Step 2: Evaluate the subpubic angle parameters. In a typical human male pelvis, the subpubic angle is acute, generally less than  $90^\circ$  (often between  $70^\circ$  to  $80^\circ$ ). In contrast, a female subpubic angle is obtuse, typically greater than  $90^\circ$  to accommodate a fetus.

Step 3: Evaluate the sciatic notch and preauricular sulcus. A narrow, deep greater sciatic notch is a classic male feature, whereas a wide notch is female. The preauricular sulcus is a groove located at the lower border of the iliac surface that is well-developed in females but usually absent or shallow in males.

Step 4: Synthesize the anthropological data. All three parameters observed by the specialist point consistently toward male anatomy.

Step 5: Determine the finality of the conclusion. Despite the advanced soft tissue decomposition, skeletal landmarks remain preserved and unaffected, allowing a definitive conclusion that the remains belong to a male individual.

**Final Answer:**

**Answer:** (B)

[Go Back to Question 6](#)



Q7.

**Solution**

**Concept:** Acute poisoning by acetylcholinesterase inhibitors results in a severe cholinergic crisis. Management mandates immediate stabilization using specific physiological antidotes to counteract lethal muscarinic receptor hyperstimulation.

**Solution:** Step 1: Deduce the nature of the poison from the pediatric clinical presentation. The combination of pinpoint pupils ( $\mu$ ), massive salivation, lacrimation, urinary incontinence, diarrhea, and severe bronchoconstriction represents the DUMBELS mnemonic characteristic of organophosphate or carbamate insecticide poisoning.

Step 2: Understand the mechanism of the toxic signs. These agents inhibit acetylcholinesterase, leading to a profound accumulation of acetylcholine at both muscarinic and nicotinic receptors.

Step 3: Analyze the immediate life-threatening features. The primary causes of mortality in a cholinergic crisis are respiratory failure driven by massive bronchial secretions, bronchoconstriction, and central respiratory depression.

Step 4: Select the appropriate immediate physiological antidote. Atropine sulfate is a competitive muscarinic receptor antagonist. It blocks excess acetylcholine at muscarinic sites, reversing deadly bronchoconstriction and drying up airway secretions.

Step 5: Differentiate from the other options. Pralidoxime is a cholinesterase rejuvenator that acts on nicotinic receptors but is not the immediate first choice over atropine for reversing acute respiratory distress. Physostigmine would worsen the condition as it is an acetylcholinesterase inhibitor.

**Final Answer:**

**Answer: (B)**

[Go Back to Question 7](#)



Q8.

**Solution**

**Concept:** Certain chemical poisons cause specific modifications to hemoglobin, creating distinct complexes that alter blood coloration and produce characteristic post-mortem appearances during forensic autopsy examinations.

**Solution:** Step 1: Identify the main post-mortem findings detailed in the case report. The autopsy reveals intense generalized internal congestion, fluid blood, and a bright, cherry-red discoloration visible across the skin, musculature, and mucous membranes.

Step 2: Correlate the color changes with potential toxicological causes. A cherry-red discoloration is highly specific for carboxyhemoglobin formation, which occurs during carbon monoxide (CO) poisoning.

Step 3: Differentiate from other similar sounding poison signs. Cyanide poisoning typically presents with a bright pink or brick-red post-mortem lividity due to histotoxic hypoxia and high oxyhemoglobin levels. Hydrogen sulfide produces a greenish discoloration due to sulfhemoglobin formation.

Step 4: Analyze the spectrophotometric data provided. Carbon monoxide binds to hemoglobin with an affinity over 200 times higher than oxygen, forming carboxyhemoglobin. This complex exhibits stable, characteristic absorption bands under spectrophotometry ( $\alpha$  and  $\beta$  bands).

Step 5: Conclude the primary culprit. Given the sudden collapse, fluid blood condition, and unmistakable cherry-red tissue discoloration matching the carboxyhemoglobin profile, carbon monoxide is the definitive toxic agent.

**Final Answer:**

**Answer: (A)**

[Go Back to Question 8](#)



Q9.

**Solution**

**Concept:** Medical ethics and legal doctrines define the boundaries of medical confidentiality. While a patient's medical information is confidential, specific exceptions apply when there is an imminent threat to human life.

**Solution:** Step 1: Evaluate the core legal dilemma presented in the scenario. A psychiatrist/physician is aware of a specific, credible, and named threat of violence made by a patient but maintains absolute confidentiality, failing to warn the endangered third party.

Step 2: Define the Tarasoff Doctrine. This legal principle originates from the landmark American case *Tarasoff v. Regents of the University of California*. It establishes that a protective privilege of confidentiality ends where public peril begins.

Step 3: Understand the duty to protect. Under this doctrine, when a clinician determines that a patient poses a serious danger of violence to a foreseeable victim, they bear a legal obligation to use reasonable care to protect the intended victim, which includes notifying the police and warning the victim directly.

Step 4: Contrast with *Res Ipsa Loquitur*. *Res Ipsa Loquitur* translates to the thing speaks for itself, which is a rule of evidence used in obvious medical negligence cases.

Step 5: Contrast with Vicarious Liability. Vicarious Liability refers to an employer's liability for the negligent actions of an employee. Thus, the Tarasoff Doctrine is the only term that defines this specific duty to protect third parties.

**Final Answer:**

**Answer: (B)**

[Go Back to Question 9](#)



Q10.

**Solution**

**Concept:** Forensic odontology utilizes age-dependent changes in human teeth to estimate the chronological age of adult skeletal remains. Gustafson's method is a standardized technique that scores specific dental parameters.

**Solution:** Step 1: Review the principles of Gustafson's method for age estimation from teeth. This method evaluates six distinct structural changes that occur chronically in human teeth over time.

Step 2: List the six valid parameters included in Gustafson's criteria. These parameters are: Attrition (*A*), Periodontitis (*P*), Secondary dentin deposition (*S*), Cementum apposition (*C*), Root resorption (*R*), and Transparency of the root (*T*).

Step 3: Analyze the options provided in the question against the established criteria. Attrition refers to the wearing down of the occlusal surface and is a valid criteria.

Step 4: Analyze root resorption and cementum apposition. Root resorption involves the gradual loss of apical dentin, and cementum apposition is the continuous accumulation of cementum layers around the root. Both are valid criteria scored from 0 to 3.

Step 5: Identify the incorrect term. Paradoxical dentinogenesis is a fabricated term that does not exist in dental physiology or forensic odontology. The actual parameter related to dentin in Gustafson's method is the physiological deposition of secondary dentin, which reduces the pulp cavity size.

**Final Answer:**

**Answer: (B)**

[Go Back to Question 10](#)



**Answer Key**

Q	Ans	Q	Ans	Q	Ans	Q	Ans	Q	Ans
1	A	2	C	3	B	4	B	5	C
6	B	7	B	8	A	9	B	10	B

