

# NEET-PG Forensic Medicine Sample Paper-5

Duration: 10 Minutes

Maximum Marks: 40

## Instructions

- This paper contains **10** Multiple Choice Questions.
- Each correct answer carries **+4** mark. Incorrect answer: **-1** marks. Only **one** correct option.
- Unattempted questions carry **0** marks.
- Use of mobile phones, smartwatches, or any electronic gadgets is strictly prohibited.

**Q1.** A 32-year-old male is brought to the emergency department after an alleged physical altercation. On examination, there is a localized collection of blood beneath the scalp that is limited by the cranial suture lines, feeling soft in the center with firm margins. The examining doctor documents this as a contusion. Under which section of the Bharatiya Nyaya Sanhita (BNS), 2023 (formerly relevant IPC sections for hurt) would the perpetrator most appropriately be charged if this injury heals within a week?

- (A) Section 115 BNS (Simple Hurt)
- (B) Section 117 BNS (Grievous Hurt)
- (C) Section 118 BNS (Voluntarily causing hurt by dangerous weapons)
- (D) Section 122 BNS (Thug)

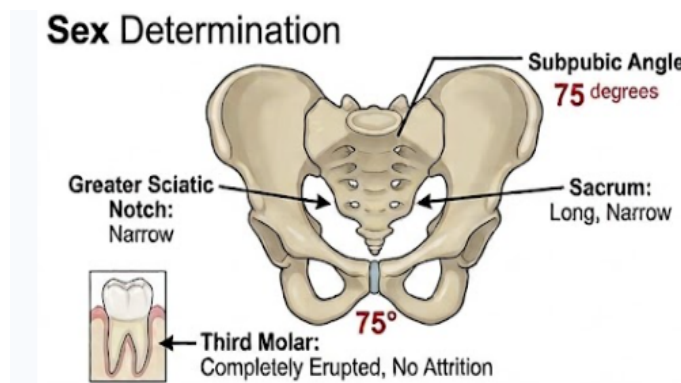
**Q2.** A 45-year-old chronic alcoholic is brought to the casualty in an altered mental state, complaining of severe abdominal pain and visual disturbances described as "looking through a snowstorm." Arterial blood gas analysis reveals a profound metabolic acidosis. Which of the following biochemical mechanisms is primarily responsible for the ocular toxicity observed in this patient?

- (A) Conversion of ethanol to acetaldehyde by alcohol dehydrogenase
- (B) Oxidation of methanol to formic acid leading to cytochrome c oxidase inhibition



- (C) Metabolism of ethylene glycol to oxalic acid causing calcium oxalate deposition
- (D) Direct destruction of retinal pigment epithelium by unmetabolized isopropyl alcohol

**Q3.** During the medicolegal autopsy of an unidentified skeletal remain, the forensic pathologist observes that the subpubic angle is  $75^\circ$ , the sciatic notch is narrow, and the sacrum is long and narrow. Additionally, the gustatory examination of the teeth shows a completely erupted third molar with no attritions. What is the most accurate assessment regarding the sex and approximate age of the individual?



- (A) Female, age below 17 years
- (B) Male, age above 17–21 years
- (C) Female, age above 25 years
- (D) Male, age below 14 years

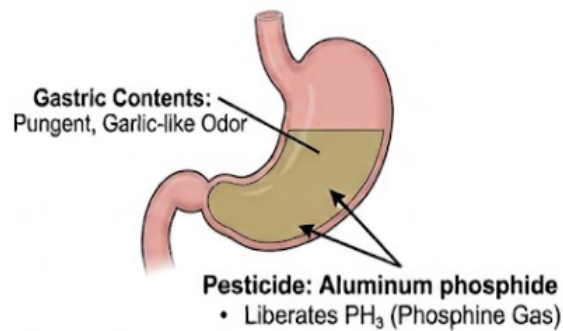
**Q4.** A 28-year-old married woman died within four years of her marriage under suspicious circumstances. The parents of the deceased allege that she was subjected to constant harassment and cruelty by her in-laws for dowry demands shortly before her death. Which section of the Bharatiya Nyaya Sanhita (BNS), 2023, deals with the presumption as to dowry death under these legal parameters?

- (A) Section 80 BNS
- (B) Section 85 BNS

- (C) Section 113B of the Indian Evidence Act / Bharatiya Sakshya Adhiniyam (BSA)
- (D) Section 304B IPC

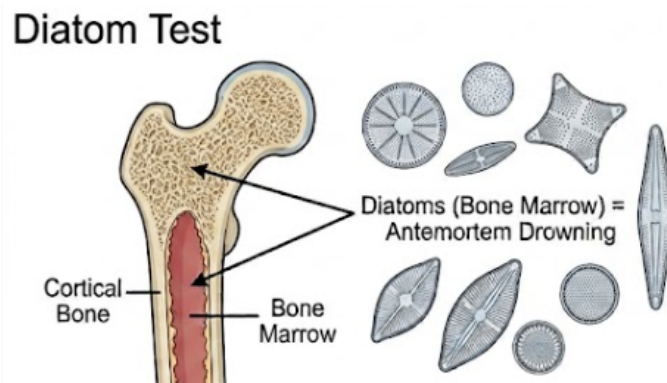
**Q5.** A farmer is brought dead to the mortuary with a history of sudden collapse while spraying pesticides in his fields. During the post-mortem examination, the pathologist notes a distinct, pungent, garlic-like odor emanating from the gastric contents, along with intense mucosal congestion and subendocardial hemorrhages. Which of the following substances is the most likely causative agent?

### Pesticide Poisoning



- (A) Organochlorine
- (B) Aluminum phosphide
- (C) Copper sulfate
- (D) Lead acetate
- Q6.** A body is retrieved from a freshwater lake. During the internal examination, the forensic pathologist notes the presence of fine, frothy lather at the mouth and nostrils, hyperinflated and doughy lungs that overlap the mediastinum, and fluid in the middle ear cavity. To confirm a diagnosis of true drowning, water samples from the lake and tissue samples from the deceased are sent for analysis. Detection of diatoms in which of the following organs would provide the most conclusive evidence of antemortem drowning?





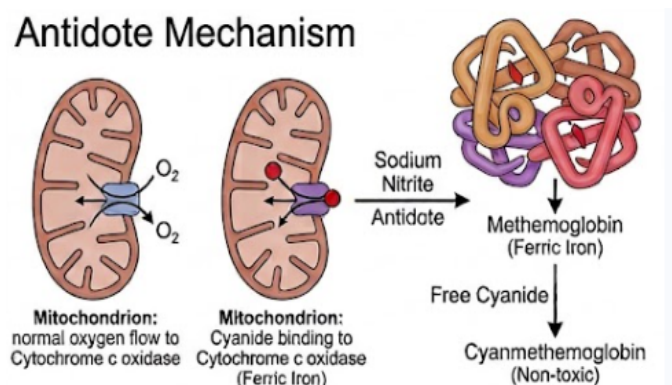
- (A) Stomach contents
- (B) Bone marrow of the femur
- (C) Lower lobe of the right lung
- (D) Superficial pleural fluid
- Q7.** A preliminary medical examiner is called to a crime scene at 6:00 AM. A dead body is found lying supine on a wooden floor. The examiner notes that post-mortem lividity is well-developed, purplish-blue in color, and fixed on the dependent parts of the back, except at areas of direct pressure. Rigor mortis is fully established all over the body. Based on these classical post-mortem changes, what is the estimated time since death?
- (A) 1 to 2 hours
- (B) 4 to 6 hours
- (C) 12 to 24 hours
- (D) 48 to 72 hours
- Q8.** A young individual was rushed to the emergency department after consuming a heavy dose of a popular plant-derived poison. The patient presents with dry mouth, extreme thirst, blurred vision, a flushed face, dilated pupils non-reactive to light, and a rapid, bounding pulse. The attending doctor suspects "deliriant poisoning." Which of the following antidotes is most specific for reversing the central effects of this plant toxin?
- (A) Atropine sulfate
- (B) Physostigmine

- (C) Pralidoxime (2-PAM)
- (D) Amyl nitrite

**Q9.** A Registered Medical Practitioner (RMP) is summoned by a court of law to give evidence in a criminal case. The physician willfully ignores the court summons and fails to appear on the specified date without providing any valid justification. Under the current legal framework, this act of non-compliance makes the practitioner liable for prosecution under which legal context?

- (A) Professional Misconduct under the National Medical Commission guidelines
- (B) Contempt of court and punishable offense for disobeying public servant's order
- (C) Civil negligence resulting in immediate suspension of license
- (D) Breach of privileged communication

**Q10.** A patient presents to the casualty with a history of ingestion of a substance characterized by a bitter almonds odor. On examination, the patient has a bright cherry-red discoloration of the skin and mucous membranes, tachypnea, and altered consciousness. Which of the following compounds acts as the primary therapeutic agent by converting hemoglobin into methemoglobin to bind this specific toxin?



- (A) Sodium thiosulfate
- (B) Sodium nitrite
- (C) Hydroxocobalamin
- (D) Ethanol



**Detailed Solutions****Q1.****Solution****Concept:**

The scenario evaluates a localized cranial injury under the Bharatiya Nyaya Sanhita (BNS), 2023. A hematoma restricted by cranial sutures is a cephalhematoma or subgaleal collection. Since it resolves within a week without permanent damage or severe pain stretching beyond fifteen days, it does not satisfy the criteria for grievous hurt. It is classified legally as simple hurt.

**Solution:**

Step 1: Identify the clinical nature of the lesion described. A localized blood collection limited by cranial sutures points to a subperiosteal hematoma. The firm margins with a soft center mimic a depressed skull fracture but represent a benign contusion.

Step 2: Evaluate the chronological parameter of the injury. The prompt notes that the injury completely heals within a single week.

Step 3: Correlate with legal provisions under the Bharatiya Nyaya Sanhita (BNS), 2023. Grievous hurt requires specific criteria such as permanent disfigurement, fractures, or severe bodily pain lasting for at least fifteen days.

Step 4: Because none of the severe criteria are fulfilled, the injury falls under the standard definition of voluntarily causing hurt. Under the modern BNS framework, this corresponds directly to Section 115.

Step 5: Differentiate options. Section 117 dictates grievous hurt, Section 118 deals with dangerous weapons, and Section 122 relates to thugs, confirming Section 115 as the accurate legal application.

**Final Answer:** Section 115 BNS (Simple Hurt)

**Answer: (A)**

[Go Back to Question 1](#)



Q2.

**Solution****Concept:**

Methanol toxicokinetics involve metabolic oxidation within the liver via alcohol dehydrogenase to formaldehyde, and subsequently via aldehyde dehydrogenase into formic acid. Formic acid targets structural components of the ocular apparatus by disrupting mitochondrial respiration through the specific inhibition of the enzyme cytochrome c oxidase.

**Solution:**

Step 1: Analyze the clinical presentation of the patient. The presence of profound metabolic acidosis combined with a visual defect described classically as "looking through a snowstorm" strongly indicates acute methanol poisoning.

Step 2: Understand the metabolic pathway of the ingested compound. Methanol is initially metabolized by alcohol dehydrogenase to form formaldehyde, which is transiently present.

Step 3: Trace the subsequent conversion. Formaldehyde is rapidly transformed into formic acid via the action of aldehyde dehydrogenase. Formic acid is the primary toxic metabolite responsible for systemic metabolic acidosis.

Step 4: Determine the precise mechanism behind the ocular symptoms. Formic acid selectively accumulates within the vitreous humor and retina, where it directly inhibits the mitochondrial enzyme cytochrome c oxidase.

Step 5: This inhibition halts the electron transport chain, causing ATP depletion, cellular hypoxia, and subsequent degeneration of retinal ganglion cells and the optic nerve.

**Final Answer:**

Oxidation of methanol to formic acid leading to cytochrome c oxidase inhibition

**Answer: (B)**

[Go Back to Question 2](#)



Q3.

**Solution****Concept:**

Skeletal identification relies heavily on pelvic morphology for sexual dimorphism and dental eruption patterns for age evaluation. A narrow subpubic angle, narrow greater sciatic notch, and long, narrow sacrum are definitive indicators of male skeletal anatomy. Complete eruption of the third molar indicates an age profile exceeding late adolescence.

**Solution:**

Step 1: Evaluate the pelvic indicators provided in the autopsy findings. The subpubic angle is documented as  $75^\circ$ . In human skeletal biology, a subpubic angle less than  $90^\circ$  is characteristic of a male pelvis, whereas females typically exhibit an angle greater than  $100^\circ$ .

Step 2: Corroborate the sex determination with secondary pelvic traits. The presence of a narrow greater sciatic notch along with a long, narrow sacrum strongly confirms male pelvic architecture.

Step 3: Analyze the dental configuration for age estimation. The forensic examination reveals a fully erupted third molar. The biological timeline for the absolute eruption of the third molar spans between 17 and 21 years of age.

Step 4: Note the absence of dental attrition, which suggests that the individual is a young adult who has only recently completed this dental development phase.

Step 5: Synthesize both parameters. The skeletal remains belong to a male individual whose chronological age is estimated to be above 17–21 years.

**Final Answer:** Male, age above 17–21 years

**Answer: (B)**

[Go Back to Question 3](#)



Q4.

**Solution****Concept:**

The legal presumption regarding a dowry death involves a specific rule of evidence where the court presumes a death to be a dowry death if harassment is proven shortly before demise. With the overhaul of criminal laws, specific statutory sections governing legal presumptions have shifted into the Bharatiya Sakshya Adhinyam (BSA), replacing the old Indian Evidence Act.

**Solution:**

Step 1: Evaluate the legal criteria presented. The deceased was a married female who died under unnatural conditions within seven years of marriage (specifically four years in this case), with documented evidence of cruelty linked to dowry demands.

Step 2: Note the distinction in the prompt's request. The question explicitly asks for the section that deals with the "presumption as to dowry death" rather than the substantive penal provision defining the crime itself.

Step 3: Differentiate the substantive penal code from procedural law. Section 80 of the BNS defines the offense of dowry death itself. However, the legal presumption utilized by courts during trials resides within evidentiary statutes.

Step 4: Identify the correct modern evidentiary section. The provision was previously Section 113B of the Indian Evidence Act. Under the current updated legal framework, this evidentiary presumption is preserved under Section 113B of the Indian Evidence Act / Bharatiya Sakshya Adhinyam (BSA).

Step 5: Conclude that while Section 80 BNS establishes the crime, Section 113B of the evidentiary act handles the operational legal presumption.

**Final Answer:** Section 113B of the Indian Evidence Act / Bharatiya Sakshya Adhinyam (BSA)

**Answer: (C)**

[Go Back to Question 4](#)



Q5.

**Solution****Concept:**

Aluminum phosphide (AIP) is a highly toxic agricultural pesticide commonly formulated as chalky tablets. Upon exposure to moisture or gastric hydrochloric acid, it undergoes a chemical reaction that liberates lethal phosphine gas ( $\text{PH}_3$ ). This gas is characterized by a prominent garlic-like odor and causes severe mucosal irritation along with localized subendocardial hemorrhages.

**Solution:**

Step 1: Analyze the post-mortem features documented during the forensic autopsy. The triad consists of an intense garlic-like odor from the stomach contents, acute mucosal congestion of the gastrointestinal tract, and subendocardial petechial hemorrhages.

Step 2: Assess the environmental context. The individual was an agricultural worker who suddenly collapsed while actively managing pesticides within a farming environment.

Step 3: Evaluate the toxic chemical profiles of the choices. Organochlorines lack a garlic odor and primarily target the central nervous system. Copper sulfate generates a distinct greenish-blue gastric discoloration. Lead acetate leads to chronic features like a lead line on gums.

Step 4: Match the characteristics with aluminum phosphide. AIP tablets release phosphine gas upon contact with stomach acid. Phosphine is highly cytotoxic, inhibiting cytochrome c oxidase and inducing oxidative stress that damages the myocardium and gastric mucosa.

Step 5: The liberation of phosphine gas delivers the characteristic garlic or decaying fish odor, making aluminum phosphide the correct diagnosis.

**Final Answer:**

**Answer: (B)**

[Go Back to Question 5](#)



Q6.

**Solution****Concept:**

The diatom test is a classic forensic tool used to distinguish between antemortem drowning and post-mortem submersion. For a diatom to enter the systemic circulation and lodge inside closed organs like the femoral bone marrow, the individual must have possessed an active, functioning circulatory system capable of transporting these microscopic organisms from the lungs to distant bones.

**Solution:**

Step 1: Understand the mechanism of diatom entry during drowning. When a living person drowns, water containing microscopic algae known as diatoms is aspirated deep into the respiratory bronchioles and alveoli under high pressure.

Step 2: Trace the path through a functional circulation. The high pressure ruptures alveolar membranes, allowing diatoms to enter pulmonary capillaries. From there, an active heartbeat pumps them into the systemic arterial circulation.

Step 3: Analyze the distribution across different tissues. Diatoms found purely in the lungs or stomach can be explained by passive contamination or water entry after death, as water can seep into these open cavities post-mortem.

Step 4: Identify the role of closed organs. Closed organs, such as the intact bone marrow of long bones like the femur, are completely isolated from external water contact after death.

Step 5: Therefore, finding diatoms inside the femoral bone marrow provides unequivocal, conclusive evidence that the individual was alive and circulating blood when water inhalation occurred, confirming antemortem drowning.

**Final Answer:**

**Answer: (B)**

[Go Back to Question 6](#)



Q7.

**Solution****Concept:**

The estimation of the post-mortem interval relies on tracking sequential changes such as algor mortis, rigor mortis, and livor mortis. Rigor mortis in tropical or temperate climates typically begins within 1 to 2 hours, becomes fully established throughout the entire musculoskeletal structure by 12 hours, remains constant for another 12 hours, and then gradually recedes.

**Solution:**

Step 1: Examine the state of post-mortem lividity (livor mortis). The findings mention that post-mortem lividity is well-developed, purplish-blue, and fully fixed on the dependent areas of the back. Fixation of lividity typically occurs between 6 to 12 hours after death.

Step 2: Analyze the status of rigor mortis. The examiner notes that rigor mortis is fully established across the entire body, from the small muscles of the jaw down to the lower extremities.

Step 3: Correlate the timeline of rigor mortis establishment. Rigor mortis requires roughly 12 hours to become completely set across all muscle groups. It then maintains this maximum rigidity for an additional 12-hour plateau phase.

Step 4: Combine the indicators. The combination of completely fixed lividity and fully present rigor mortis throughout the body strongly indicates a post-mortem interval spanning between 12 and 24 hours.

Step 5: Exclude other options. A time frame of 1–2 or 4–6 hours is too early for fixed lividity or complete rigor, while 48–72 hours would show total decomposition and absent rigor.

**Final Answer:**

**Answer:** (C)

[Go Back to Question 7](#)



Q8.

**Solution****Concept:**

Deliriant poisoning caused by anticholinergic plants like *Datura stramonium* produces a classic toxidrome marked by competitive inhibition of acetylcholine at muscarinic receptor sites. To reverse these central toxic manifestations, an antidote must be capable of crossing the blood-brain barrier to effectively raise synaptic acetylcholine concentrations.

**Solution:**

Step 1: Identify the clinical toxidrome presented by the patient. The symptoms of dry mouth, extreme thirst, blurred vision, flushed face, dilated non-reactive pupils, tachycardia, and delirium correspond to an acute anticholinergic overdose.

Step 2: Recognize the specific plant genus responsible. This classic deliriant syndrome is typically caused by ingestion of *Datura* or *Atropa belladonna*, which contain tropane alkaloids like atropine and scopolamine.

Step 3: Determine the physiological requirement for an antidote. While peripheral symptoms can be managed supportively, the severe central nervous system effects require an acetylcholinesterase inhibitor.

Step 4: Compare available acetylcholinesterase inhibitors. Neostigmine and pyridostigmine possess quaternary ammonium structures that carry a permanent charge, preventing them from crossing the blood-brain barrier.

Step 5: Physostigmine is a tertiary amine compound that readily crosses the blood-brain barrier. It inhibits acetylcholinesterase in the central nervous system, increasing acetylcholine to overcome the competitive blockade, making it the specific antidote.

**Final Answer:**

**Answer: (B)**

[Go Back to Question 8](#)



Q9.

**Solution****Concept:**

A medical practitioner is legally obligated to obey a subpoena or official court summons. A witness summons issued by a court of law is a formal legal order command. Willful failure to appear before the court without a legitimate, pre-authorized medical or personal excuse constitutes a criminal offense involving intentional disobedience to public servants.

**Solution:**

Step 1: Define the nature of a court summons. A subpoena or court summons is an imperative order issued by a judicial authority directing an individual to appear at a specified time to deliver testimony.

Step 2: Evaluate the practitioner's action. The Registered Medical Practitioner willfully ignored the summons and failed to attend without providing any legitimate, legally acceptable explanation.

Step 3: Distinguish between ethical misconduct and criminal behavior. While missing an appointment or violating etiquette may fall under professional misconduct with the National Medical Commission, ignoring a court order is a direct violation of state penal laws.

Step 4: Identify the specific legal category. Failing to obey an official order issued by a public servant or court constitutes contempt of the lawful authority of public servants, which is a punishable offense.

Step 5: This legal breach makes the practitioner criminally liable for disobeying an order promulgated by a public servant, distinct from civil negligence or professional ethical lapses.

**Final Answer:**

Contempt of court and punishable offense for disobeying public servant's order

**Answer: (B)**

[Go Back to Question 9](#)



Q10.

**Solution****Concept:**

Cyanide poisoning impairs cellular respiration by binding to the ferric ( $\text{Fe}^{3+}$ ) ion of cytochrome c oxidase within the mitochondrial electron transport chain. The therapeutic strategy behind using nitrites involves intentionally converting a portion of circulating hemoglobin into methemoglobin, which possesses a high affinity for cyanide ions.

**Solution:**

Step 1: Identify the specific poisoning case from the diagnostic clinical features. A historical report of a bitter almonds odor combined with cherry-red skin and mucus membrane discoloration points directly to acute cyanide poisoning.

Step 2: Understand the molecular pathology of cyanide. Cyanide binds tightly to the ferric ( $\text{Fe}^{3+}$ ) iron of cytochrome a3 within cytochrome c oxidase, blocking the cell's ability to use oxygen and leading to cellular choking.

Step 3: Analyze the pharmacological mechanism of the nitrites. Sodium nitrite is administered intravenously to deliberately oxidize the ferrous ( $\text{Fe}^{2+}$ ) iron of normal hemoglobin into ferric ( $\text{Fe}^{3+}$ ) iron, producing methemoglobin.

Step 4: Evaluate the role of methemoglobin. Methemoglobin competes successfully with cytochrome c oxidase for free cyanide ions because of its high affinity for the toxin. It binds with cyanide to form non-toxic cyanmethemoglobin.

Step 5: This biochemical diversion removes cyanide from the mitochondria, restoring cellular respiration before sodium thiosulfate converts it into thiocyanate for renal excretion. Thus, sodium nitrite is the primary methemoglobin-forming agent.

**Final Answer:**

**Answer: (B)**

[Go Back to Question 10](#)



**Answer Key**

| Q | Ans | Q | Ans | Q | Ans | Q | Ans | Q  | Ans |
|---|-----|---|-----|---|-----|---|-----|----|-----|
| 1 | A   | 2 | B   | 3 | B   | 4 | C   | 5  | B   |
| 6 | B   | 7 | C   | 8 | B   | 9 | B   | 10 | B   |

